

Boerhaave's syndrome – tension hydropneumothorax and rapidly developing hydropneumothorax: two radiographic clues in one case

Lam Nguyen Ho, Ngoc Tran Van & Thuong Vu Le

Department of Internal Medicine, Faculty of Medicine, University of Medicine and Pharmacy, Ho Chi Minh City, Vietnam.

Keywords

Boerhaave's syndrome, hydropneumothorax, methylene blue, pleural effusion, tension pneumothorax.

Correspondence

Nguyen Ho Lam, Department of Internal Medicine, Faculty of Medicine, University of Medicine and Pharmacy, 217 Hong Bang Street, Ward 11, District 5, Ho Chi Minh City, Vietnam. E-mail: bsholam1986@gmail.com

Received: 17 January 2016; Revised: 25 February 2016; Accepted: 10 March 2016

Respirology Case Reports, 4 (4), 2016, e00160

doi: 10.1002/rcr2.160

Abstract

Boerhaave's syndrome is a rare and severe condition with high mortality partly because of its atypical presentation resulting in delayed diagnosis and management. Diagnostic clues play an important role in the approach to this syndrome. Here, we report a 48 year-old male patient hospitalized with fever and left chest pain radiating into the interscapular area. Two chest radiographs undertaken 22 h apart showed a rapidly developing tension hydropneumothorax. The amylase level in the pleural fluid was high. The fluid in the chest tube turned bluish after the patient drank methylene blue. The diagnosis of Boerhaave's syndrome was suspected based on the aforementioned clinical clues and confirmed at the operation. The patient recovered completely with the use of antibiotics and surgical treatment. In this case, we describe key findings on chest radiographs that are useful in diagnosing Boerhaave's syndrome.

Introduction

Boerhaave's syndrome or spontaneous esophageal rupture was first described by the Dutch physician Herman Boerhaave in 1724. Nowadays, it is really a diagnostic challenge to most clinicians. Several clinicians have published case reports to find out key findings on chest radiographs to resolve this problem. Tension pneumothorax [1–3] and rapidly developing pleural effusion [4,5] were reported as two radiographic clues in diagnosing Boerhaave's syndrome. Here, we report a case of Boerhaave's syndrome presented as tension hydropneumothorax and rapidly developing hydropneumothorax simultaneously.

Case Report

A 48 year-old male patient was hospitalized with fever and left chest pain. His past history was not remarkable. One day before hospitalization, he drank alcohol and vomited twice. After the second vomiting episode, he immediately developed

severe left chest pain radiating into the interscapular area. Subsequently, he had fever and chills. He was hospitalized and diagnosed with pneumonia and respiratory failure at a rural district hospital. He was transferred to a tertiary hospital after being treated with one dose of antibiotics including ceftriaxone and gentamicin. On clinical examination, his blood pressure was 100/60 mmHg, pulse rate 106/min, temperature 37°C, respiratory rate 26/min, and peripheral capillary oxygen saturation (SpO₂) 96% with 3 L/min of oxygen via nasal cannula. The lower left hemithorax was dull to percussion and had both decreased breath sounds and decreased tactile fremitus.

The white blood cell count was 11,100/mm³; 88.7% was neutrophil. Other blood tests were in normal range. Chest radiograph on admission into the tertiary hospital (at 22:00) showed hydropneumothorax in the left hemithorax (Fig. 1A). At this time, he was diagnosed with left lung abscess and acute respiratory failure. Therefore, he was administered intravenous antibiotics. However, his clinical status worsened rapidly: his SpO₂ decreased to 80% with

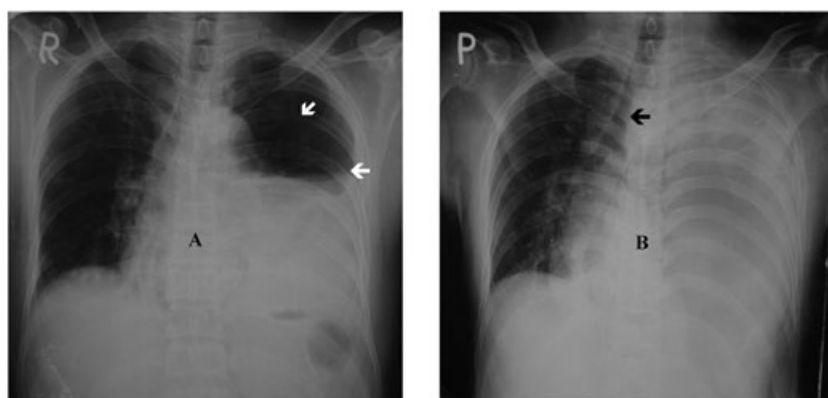


Figure 1. Two consecutive chest radiographs with tension hydropneumothorax. A) Chest radiograph on admission in the tertiary hospital with left hydropneumothorax, the visceral pleura edge is discernible (white arrows). B) A supine chest radiograph taken 22 h later shows left hemithorax white-out and increasing tracheal deviation to the right (black arrow).

6 L/min of oxygen via nasal cannula, his blood pressure was 80/50 mmHg, and he was agitated. He underwent the second chest radiograph 22 h after the first radiograph (at 20:00 of the next day). The second radiograph showed large pleural effusion in the left hemithorax (Fig. 1B). His clinical status was improved after fluid resuscitation, therapeutic thoracentesis, and chest tube insertion. The amylase level in the pleural fluid was 9713.4 U/L, while the serum amylase was 38.2 U/L. The contrast-enhanced chest computed tomography showed left pleural effusion and mediastinal air at the lower part of the esophagus. The fluid in the chest tube turned bluish after he drank methylene blue (Fig. 2). The operation demonstrated a perforation with 20 mm in length at the lower part of the esophagus, just 2 cm above the stomach. The diagnosis of Boerhaave's syndrome was established. The esophageal perforation was sewed. Two weeks after the operation, the esophageal endoscopy showed that the sewed perforation was healing well. The patient recovered completely and was discharged after 26 days.

Discussion

Patients with Boerhaave's syndrome may present slightly different from the Mackler's triad of vomiting, chest pain, and subcutaneous emphysema, for example, our clinical case presented with fever, chest pain, and vomiting. We suspected the diagnosis of Boerhaave's syndrome thanks to two key findings on two consecutive chest radiographs: the first with tension hydropneumothorax on hospital admission and the second with rapidly developing hydropneumothorax on the next day. The spontaneous rupture of the esophagus was investigated as one of the differential diagnoses of rapidly developing hydropneumothorax. The other causes of rapidly developing hydropneumothorax or pleural effusion include lung abscess rupture into pleural space, haemothorax, group

A beta-hemolytic streptococcal infection, and thoracic duct disruption. Increasing left intrapleural pressure appeared indirectly through findings such as tracheal deviation to the right and hypotension that improved with decompression (thoracentesis and chest drainage).

In patients with chest tube inserted, diagnosis of esophageal perforation into pleural space should be considered with the following characteristics: a concordance of drainage output according to meal, a bluish discoloration of chest tube after drinking methylene blue, and biliary and food contents within chest tube. The fluid in the chest tube presenting a bluish



Figure 2. The drainage system shows the fluid in the chest tube presenting a bluish discoloration (white arrow).

Table 1. Published case reports of Boerhaave's syndrome presented as tension pneumothorax or rapidly evolving pleural effusion.

Tension pneumothorax				Rapidly evolving pleural effusion			
Author & year	Vomiting	Pleural fluid	Outcome	Author & year	Vomiting	Period of increasing pleural fluid	Outcome
Zamir G. et al 1995 [2]	Yes	Yes	Survived	Wise M.P. et al 2009 [5]	Yes	4 hours	Survived
Onyeka W.O.C. et al 1999 [1]	Yes	Yes	Died	Hingston C.D. et al 2010 [4]	Yes	32 hours	Survived
Vallabhajosyula S. et al 2015 [3]	Yes	Yes	Survived				

discolouration after drinking methylene blue suggested the final diagnosis in our case. This is a simple way to test the hypothesis of esophageal perforation into pleural space.

A tension pneumothorax and a rapidly evolving pleural effusion were diagnostic clues of Boerhaave's syndrome in patients with a medical history of vomiting. Table 1 summarizes published case reports with these diagnostic clues. Most cases with tension pneumothorax showed pleural effusion appearing simultaneously in the same side. Therefore, tension pneumothorax in these cases should be interpreted as tension hydropneumothorax. [1–3] In our case, the first chest radiograph only showed a small pneumothorax because lung markings were clearly visible, and the visceral edge in the upper left hemithorax could be identified with the great caution. Therefore, if we recognized tension hydropneumothorax on chest radiograph at the time of admission, Boerhaave's syndrome should be investigated and established before the patient worsens. In conclusion, radiographic clues should be identified early because they are useful in diagnosing Boerhaave's syndrome.

Disclosure Statement

No conflict of interest declared.

Appropriate written informed consent was obtained for publication of this case report and accompanying images.

Acknowledgments

The authors thank Dr. Nguyen Van Tho who assisted to edit the English of this manuscript. The authors also acknowledge Dr. Vu Huu Vinh who took part in conducting the operative treatment for this patient.

References

1. Onyeka WO, Booth SJ. 1999. Boerhaave's syndrome presenting as tension pneumothorax. *J. Accid. Emerg. Med.* 16:235–236.
2. Zamir G, Kluger Y, Muggia-Sullam M. 1995. Tension pneumothorax – another presentation of spontaneous rupture of the esophagus. *Dig. Surg.* 12:124–125.
3. Vallabhajosyula S, Sundaragiri PR, Berim IG. 2015. Boerhaave syndrome presenting as tension pneumothorax: first reported north american case. *J. Intensive Care Med.* DOI:10.1177/0885066615606698.
4. Hingston CD, Saayman AG, Frost PJ, et al. 2010. Boerhaave's syndrome—rapidly evolving pleural effusion: a radiographic clue. *Minerva Anesthesiol.* 76:865–867.
5. Wise MP, Salmon J, Maynard N. 2009. Boerhaave's syndrome: a diagnostic conundrum. *BMJ Case Reports* 209: bcr07.2008.0375.